140 Electrosurgery

Sheldon V. Pollack

Chapter Contents

Indications/Contraindications 2444
Preoperative History and Considerations 2444
Description of Techniques 2445
Variations/Unusual Situations 2447
Postoperative Care 2448
Complications 2448
Electroepilation 2449
Iontophoresis 2449
Future Trends 2449

Synonym: ■ Radiosurgery (historical)

Key features

- Electrosurgery encompasses a group of procedures by which tissue is removed or destroyed through the application of electrical energy
- True ***electrocautery*** uses direct current to create a red-hot tip, which can be safer for patients with pacemakers and implantable cardioverter-defibrillators
- In modern electrosurgery, high-frequency alternating current is converted to heat within the treated tissues as a result of resistance to its passage
- ***Electrodesiccation*** is superficial ablation by touching the tissue with a monoterminal device
- ***Electrofulguration*** is superficial ablation via the use of a monoterminal device whose electrode is held at a slight distance from the tissue, allowing a spark to jump to the tissue
- ***Electrocoagulation*** uses a biterminal device for deeper coagulation
- ***Electrosection*** uses a biterminal device to cut while achieving hemostasis by mild lateral heat spread
- In order to minimize adverse sequelae, lateral heat spread should be kept to a minimum by using the appropriate waveform, power setting, and electrode size

INTRODUCTION AND BACKGROUND

Definition

Modern electrosurgery encompasses a group of techniques by which high-frequency alternating electrical current is applied to living tissues in order to achieve superficial coagulation, deep coagulation, or cutting of the skin. Since living tissue is a poor conductor of electricity, the flow of electrical current is hampered and builds up at the site of application. This resistance to the flow of electricity results in its conversion to heat. The use of different varieties of electrosurgical current, each characterized by a distinctive waveform, results in unique biologic outcomes, including desiccation, coagulation, or section of treated skin.

Electrocautery

The forerunner of modern electrosurgery was electrocautery (from Greek *kauterion*, branding iron)[1]. In electrocautery, invented in 1875, a metal wire is heated by resistance to the flow of direct current electricity, as in an electric toaster. Hemostasis (even in a wet field) can be obtained with electrocautery, but the resulting third-degree burn may result in prolonged healing times and may cause inferior cosmetic outcomes.

Of note, electrocautery, with its hot element (Fig. 140.1), is different from modern electrosurgery, in which high-frequency alternating current is applied via an unheated electrode. Electrocautery units are of value for providing hemostasis for surgical patients with implantable cardioverter-defibrillators (ICDs) because external electromagnetic fields may compromise the function of these devices; with modern-era permanent pacemakers the latter is primarily a concern when electrosurgery is performed within 5 cm of the device[2]. A number of electrocautery units are currently produced; among them is the Geiger TCU Thermal Cautery Unit. Disposable battery-powered electrocautery instruments are also available, but the desired temperature can diminish during contact with tissue.

Historical Aspects

Although used by most dermatologists on a daily basis, high-frequency electrosurgery could not have been developed if several major advances in the knowledge of electricity had not occurred. In order for alternating current electricity to be utilized for medical purposes, it was necessary for high-frequency currents to be produced. A generator that could provide such current was developed in 1889 by Thompson, who noted heat in his wrists when current was passed through his hands when immersed in saline solution[3]. Experiments conducted by Jacques Arsène d'Arsonval in 1891 established that the application, in human subjects, of electric currents with frequencies greater than 10 000 cycles per second (10 KHz) failed to cause neuromuscular stimulation and the associated tetanic response[4,5]. Also in the 1890s, Oudin, following some modifications to d'Arsonval's equipment, was able to generate a spray of sparks that caused superficial tissue destruction.

At the turn of the twentieth century, Rivière conceived the notion of using very small treatment electrodes in order to concentrate the current density. This would enable one to treat a skin lesion with an electric spark[6]. Walter de Keating-Hart and Pozzi[7] in 1907 introduced the term "fulguration" (from Latin *fulgur*, lightning), referring to the superficial carbonization that resulted when the spark from the Oudin coil was used to treat skin. They claimed that this modality was ideal for treating skin cancer and that the spark could selectively destroy tumor cells by interfering with their source of nutrition.

In 1909, Doyen[8] introduced the term "electrocoagulation" (from Latin *coagulare*, to curdle) to describe a different form of electrosurgery in which tissue was touched directly with the treatment electrode and an indifferent electrode was added to the circuit. The indifferent electrode allowed for direct removal of the electricity entering the patient and caused the latter to flow back into the electrosurgical device. By removing this static energy build-up, shocks were avoided in surgeons and other bystanders. The amperage was effectively increased while the "recycling" of electrical current allowed for lower voltages to be utilized. The current produced with this biterminal arrangement penetrated more deeply than fulguration and directly coagulated tissues rather than causing only surface carbonization. Doyen claimed that this more deeply penetrating current was more likely to be effective in the destruction of tumor cells.

William Clark, in 1911, reported on the use of an electrosurgical output that caused dehydration of tissue without carbonization at the surface[9]. He substituted a multiple spark gap for the usual single one

Downloaded for Anonymous User (n/a) at Egyptian Knowledge Bank from ClinicalKey.com by Elsevier on March 10, 2024. For personal use only. No other uses without permission. Copyright ©2024. Elsevier Inc. All rights reserved.

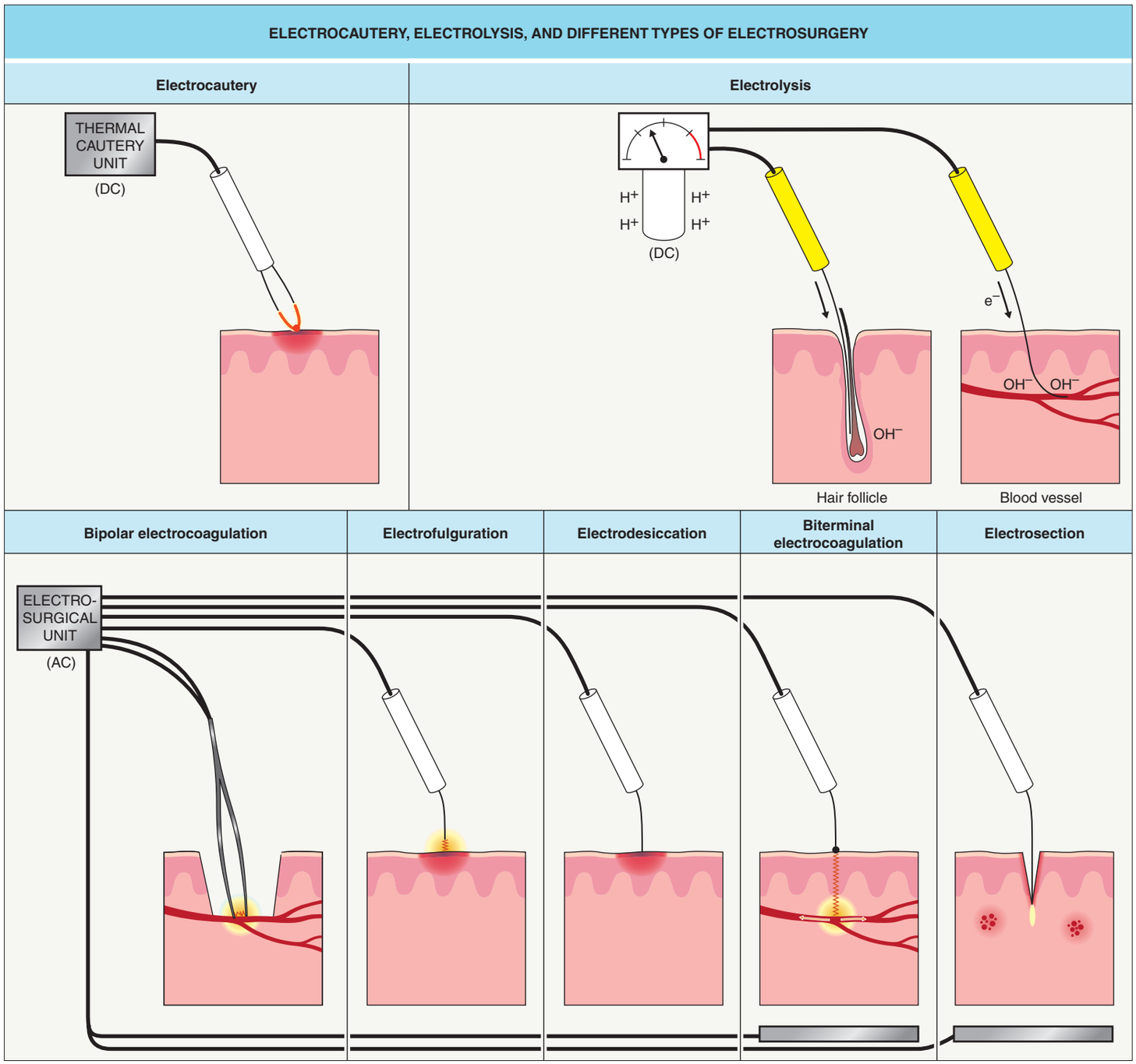

Fig. 140.1 Electrocautery, electrolysis, and different types of electrosurgery. AC, alternating current; DC, direct current; e^-, electron; H^+, proton; OH^-, hydroxide ion.

in a monoterminal Oudin current generator. This provided a smoother current that resulted in the production of fine sparks as opposed to the long, thick sparks seen with electrofulguration. Clark used the term "desiccation" (from Latin *desiccare*, to dry out) to describe this action.

The next major event in the development of electrosurgery came in 1923 when Dr George A. Wyeth, a noted tumor surgeon, used electrosurgery for cutting tissues[10]. His apparatus, which he termed an "endotherm knife" (Greek *endo*, within; *thérmē*, heat), used a thermionic vacuum tube instead of a spark gap[11]. Wyeth called the technique "electrothermic endothermy". He believed that the technique was particularly applicable to tumor surgery since it sealed off not only the smaller blood vessels but also the lymphatics that might otherwise provide for dissemination of metastatic disease.

A Harvard physicist, William Bovie, PhD, probably made the most important contribution to the development of electrosurgery. With financial assistance from the Liebel-Flarsheim Company of Cincinnati, he built an operating room electrosurgical device that offered both coagulating and cutting currents[12]. Dr Harvey Cushing, a distinguished neurosurgeon, became quite interested in these techniques and, with Bovie at the controls, began using electrosurgery for controlling bleeding and cutting through tissues during surgical procedures at Peter Bent Brigham Hospital in 1926. Dr Cushing's favorable impressions of electrosurgery assured acceptance of this technique by the surgical world. The subsequent impact of Bovie's machine upon medicine was so great that the word "bovie" is still often used generically as a noun to refer to an electrosurgical apparatus or even as a verb to describe the act of performing electrosurgery[13].

Electrosurgical Devices and Outputs

The circuitries of all electrosurgical instruments share certain design features necessary for production of suitable electrical outputs for electrosurgery. Standard household current first passes through a transformer which alters the voltage, providing the levels and characteristics

Downloaded for Anonymous User (n/a) at Egyptian Knowledge Bank from ClinicalKey.com by Elsevier on March 10, 2024. For personal use only. No other uses without permission. Copyright ©2024. Elsevier Inc. All rights reserved.

APPLICATIONS OF DIFFERENT WAVEFORMS IN ELECTROSURGERY			
60 Hz Alternating current		Unaltered sine wave	
Spark gap circuit			
Modality	**Electrode configuration**		**Waveform**
Electrodesiccation	Monoterminal	Markedly damped	
Electrofulguration	Monoterminal	Markedly damped	
Electrocoagulation	Biterminal	Moderately damped	
Electronic circuit			
Modality	**Electrode configuration**		**Waveform**
Electrocoagulation	Biterminal	Partially rectified	
Electrosection, with coagulation	Biterminal	Fully rectified	
Electrosection, pure cutting	Biterminal	Fully rectified, filtered	

Fig. 140.2 Applications of different waveforms in electrosurgery.

required for the instrument's various circuit functions. The current next travels through an oscillating circuit that may employ a spark gap, a thermionic vacuum tube, or solid-state transistors to increase electrical frequency. Finally, this altered electrical energy is delivered to the treatment electrode.

Each electrosurgical current produces its own unique wavy pattern of current flow, or *waveform*. The latter may be either *damped* or *undamped*, depending on the type of oscillating circuit used. In general, damped waveforms provide electrodesiccation and electrofulguration, whereas the application of moderately damped and undamped currents results in electrocoagulation and cutting currents, respectively (Fig. 140.2). The spark gap generator produces a damped wave, consisting of bursts of energy in which successive wave amplitudes gradually return to zero. This occurs due to the resistance to energy flow presented by the gap.

Use of a thermionic tube results in a more uniform output. The valve tube circuit is able to neutralize the internal resistance responsible for the damping effect seen in the spark gap circuit, and the amplitude of output therefore remains unchanged. Depending on the circuitry used, the output can be moderately damped (partially rectified) or slightly damped (fully rectified). A filtered, fully rectified output is essentially continuous and uniform, similar to an undamped wave. The different types of waveforms each result in different biologic outcomes and are, therefore, used for different electrosurgical procedures[14,15].

Terminology: Monopolar, Bipolar, Monoterminal, and Biterminal

The terms *monopolar* and *bipolar* denote the number of tissue contacting tips at the end of the surgical electrode. When the surgical electrode has only one tip projecting from its end, it is a monopolar electrode. If it has two tips, it is a bipolar electrode. Therefore, an electrosurgical forceps (that plugs into two ports on the electrosurgical device) is considered to be bipolar, as opposed to a pointed electrode, which is monopolar (and plugs into one port on the device).

Monoterminal refers to the use of a treatment electrode without an indifferent or dispersive electrode ("ground plate"). *Biterminal* denotes that both treatment and indifferent electrodes are used (see Fig. 140.1). Such is the case with electrocoagulation and electrosection, in which use of the indifferent plate, although not *technically* necessary for the machine to work, will definitely enhance the efficiency of the electrosurgical apparatus. In biterminal electrosurgical applications, there is "recycling" of the energy that comes out of the treatment electrode, passes through the patient and is then removed from the patient via the indifferent electrode. Electrodesiccation and its variant, electrofulguration, are monoterminal procedures in which the indifferent electrode serves no purpose and, in most instances, is not even connected to the patient.

A simple way to visualize this is to think of the wires coming out of the machine as terminals. If only one wire (the handpiece for the electrode) is attached to the machine, then the application is monoterminal in nature. If, in addition, a "ground plate" is used, requiring a second wire to be attached to the machine, then the procedure is biterminal (see Fig. 140.6).

When a ball electrode is used to electrocoagulate a bleeding vessel, one is using biterminal, monopolar electrosurgery. In the case of bipolar forceps in which the electrode is connected to both the active and the dispersive electrode termini, we are using a bipolar modality.

INDICATIONS/CONTRAINDICATIONS

The simplest way to think of electrosurgical applications in the clinical setting is to consider the three major capabilities of electrosurgery units. These include superficial tissue destruction (electrodesiccation), deep tissue destruction (electrocoagulation), and cutting (electrosection)[16,17]. Destruction or excision of skin lesions by electrosurgery should be accomplished with the smallest possible amount of damage to normal tissues. Whether electrosurgery, cryosurgery or ablative laser surgery is used, the greater the penetration of the destructive modality into the skin, the greater the likelihood that unacceptable scarring will result. Because the destructive effects of electrocoagulation extend more deeply than those of electrodesiccation, the clinician must consider the histologic characteristics of the lesion to be treated when selecting the appropriate current. A partial list of dermatologic conditions that are commonly treated by each electrosurgical modality is found in Table 140.1.

There are no absolute contraindications to the use of electrosurgery, but precautions should be taken during the treatment of patients with cardiac implantable electronic devices (see Variations/Unusual Situations, below).

PREOPERATIVE HISTORY AND CONSIDERATIONS

The preoperative assessment of patients undergoing electrosurgery should concentrate on potential hazards to either the patient or the treatment team. A patient history of previous allergic reactions to skin cleansers, anesthetics, or postoperative topicals and dressings should be sought. Electrosurgery should be used with care in patients with cardiac implantable electronic devices.

Smoke evacuation equipment should always be available to safely remove the smoke plume when extensive electrosurgery, particularly electrosection, is performed. In such procedures, the operator and assistants should wear masks and use eye protection to prevent exposure to smoke-borne microbes and noxious particles. Gloves should always be worn when electrosurgical procedures are performed.

Preparatory to electrosurgery, the lesion and surrounding skin should be cleansed with a non-alcoholic skin cleanser such as chlorhexidine or povidone iodine. There is a potential for alcohol to ignite with electrosurgery, so it should be avoided or allowed to thoroughly dry prior to therapy.

Local anesthesia, usually via 1% lidocaine with epinephrine (adrenaline), is almost always used when performing electrosurgery. The usual exception is in the treatment of small facial telangiectasias, in which anesthesia is omitted. Local infiltration is most often used for anesthetizing localized superficial lesions, whereas field blocks and/or nerve blocks should be considered when performing larger electrosurgical procedures such as rhinophyma repair. When a local anesthetic is used prior to treatment of a dome-shaped lesion, such as a large angioma, it is helpful to massage the swollen anesthetized treatment site prior to electrosurgery, in order to flatten it. This prevents the development of a depressed scar subsequent to the procedure.

Prior to activating the electrosurgery unit, the operator should determine that the appropriate current and power settings for the

Downloaded for Anonymous User (n/a) at Egyptian Knowledge Bank from ClinicalKey.com by Elsevier on March 10, 2024. For personal use only. No other uses without permission. Copyright ©2024. Elsevier Inc. All rights reserved.

COMMON DERMATOLOGIC INDICATIONS FOR ELECTROSURGERY
Electrofulguration/electrodesiccation (superficial skin ablation)
Acrochordon
Actinic keratosis
Angioma (small)
Dermatosis papulosa nigra
Epidermal nevus
Hemostasis (capillary bleeding)
Lentigo
Seborrheic keratosis
Verruca plana
Electrocoagulation (deep skin ablation)
Angiofibroma
Angioma (large)
Basal cell carcinoma
Bowen disease (squamous cell carcinoma *in situ*)
Hemostasis (arterial bleeding)
Hirsutism (electroepilation)
Ingrown toenail matrixectomy
Banal melanocytic nevi
Sebaceous hyperplasia
Squamous cell carcinoma
Syringoma
Telangiectasia
Trichoepithelioma
Verruca vulgaris (all locations)*
Electrosection (skin incision/excision)
Acne keloidalis nuchae
Blepharoplasty incision
Debulking procedures
Rhinophyma repair
Rhytidectomy incisions and undermining
Scar revision
Shave removal of benign skin lesions (e.g. fibromas, melanocytic nevi)
Skin flap incisions and undermining
Skin resurfacing
Surgical excision of malignant or benign skin lesions
*Some clinicians use electrodesiccation and curettage.

Table 140.1 Common dermatologic indications for electrosurgery.

particular procedure have been selected, that the dispersive electrode has been properly placed, and that the correct treatment electrode has been chosen. Disposable sleeves that slip over the handle of the wand and disposable electrode tips are often utilized. It is unacceptable to use the same electrode tip on multiple patients without sterilization, erroneously assuming that heat will destroy pathogens.

DESCRIPTION OF TECHNIQUES

Electrodesiccation and Electrofulguration

For very superficial lesions, such as those involving only the epidermis, electrosurgical destruction by *electrodesiccation* can be achieved with little, if any, scarring. The markedly damped, high-voltage current generated by spark gap electrosurgical units causes superficial tissue damage by dehydration of the treatment site. It is delivered in a monoterminal (concentrative) fashion (see Fig. 140.1). If the electrode is held at a slight distance from the tissue, a spark is formed between the electrode and the tissue. This technique, termed *electrofulguration*, achieves very superficial destruction because the surface carbonization it produces insulates the underlying tissues from thermal heat spread.

Dermatologists who employ a Hyfrecator® or similar device often utilize this type of waveform. As the surface becomes charred by sparking at the surface, it is common for blood to appear in droplets that penetrate through the surface char. This is because the electrical current does not penetrate deeply enough to seal nearby blood vessels. Therefore, when surgical excision is undertaken, electrocoagulation is a better current to employ in order to provide hemostasis (see below). However, for treatment of small very superficial epidermal lesions, electrofulguration should be considered the waveform of choice. For example, it is very effective for the treatment of dermatosis papulosa nigra.

Electrodesiccation is the method of choice when superficial tissue destruction is desired. For example, it is ideal for treatment of epidermal lesions such as seborrheic or actinic keratoses (Fig. 140.3), acrochordons, verrucae planae, or small epidermal nevi. Hemostasis of mild capillary bleeding can also be achieved by use of electrodesiccation. A standard technique for treating keratoses by this method is to move the electrode slowly across the surface of the lesion (for small lesions) or to insert it directly into the lesion (for larger lesions), while applying current at a low power setting. After a few seconds, the lesion bubbles as the epidermis separates from the underlying dermis. It can then be easily removed with a curette or simply by rubbing a piece of gauze across the treatment site. The clinical endpoint in treating epidermal lesions is punctate bleeding, which is controlled with pressure, by spot electrocoagulation, or by topical hemostatic agents such as aluminum chloride. More profuse bleeding indicates probable damage to the dermis, with a greater likelihood of subsequent scarring. Extremely small superficial lesions can be treated by electrofulguration, which causes the least amount of damage to adjacent tissues.

Electrocoagulation

In electrocoagulation, a moderately damped current is applied in a *biterminal* manner (both concentrative and dispersive electrodes are used). This current is of higher amperage and lower voltage than that utilized for electrodesiccation. Because this type of current penetrates more deeply, it has the potential for greater tissue destruction.

Electrocoagulation is particularly useful for deep tissue destruction and surgical hemostasis. It is our preferred modality for treating small and uncomplicated primary basal cell and squamous cell carcinomas, as well as other lesions such as trichoepitheliomas, which extend into the dermis. Much of the literature refers to "curettage and electrodesiccation (C&E)" or "electrodesiccation and curettage (ED&C)", but, in fact, electrocoagulation may be the preferred electrosurgical waveform for all but the most superficial tissue destruction.

When performed properly, electrosurgery plus curettage yields cure rates of 90%–95% for uncomplicated basal cell carcinomas and superficial squamous cell carcinomas, making it an efficient, cost-effective treatment. Thorough curettage is likely the key element affecting success. Initially, a large curette (4–6 mm) is used to debulk the tumor, followed by a smaller curette (2 mm). The curette should be scraped across the surface of the treatment site in every direction, from superior to inferior, inferior to superior, left to right and right to left, using fairly firm downward pressure. In this way, all tumor extensions are eradicated.

After thorough curettage, the electrode is brought into direct contact with the tissue to be treated and is moved slowly around the periphery and across the curetted portion of the lesion, which eventually becomes charred. A curette may then be used to gently remove the charred tissue. For treatment of skin cancers, this procedure is repeated two or more times in an attempt to remove any small tumor extensions (Fig. 140.4). During the last curettage, a very small curette (1 mm) may be used to remove the final tiny "roots" of the tumor. Scarring must be expected with this procedure, and wounds following curettage and electrosurgery are allowed to heal by second intention.

Electrocoagulation is also effective for treatment of superficial telangiectasias (Fig. 140.5), unwanted hair (electroepilation), and ingrown toenails (electrosurgical matrixectomy). Hemostasis using electrocoagulation can be achieved by either monopolar or bipolar means. Because the electrosurgical energy may be transmitted for several millimeters along the vessel wall, it is important to use the minimum effective exposure time and power setting in order to prevent delayed bleeding from damaged vessels. We often use monopolar electrocoagulation, in which the electrode is touched directly to the bleeding vessel. Coagulation can also be achieved by touching the electrode to a hemostat that has been clamped on the severed vessel. In bipolar electrocoagulation (Fig. 140.6), a bipolar forceps is used to provide more directed pinpoint hemostasis. Electrocoagulation current delivered in this manner causes less adjacent tissue damage but requires a dry operative field to be effective.

Downloaded for Anonymous User (n/a) at Egyptian Knowledge Bank from ClinicalKey.com by Elsevier on March 10, 2024. For personal use only. No other uses without permission. Copyright ©2024. Elsevier Inc. All rights reserved.

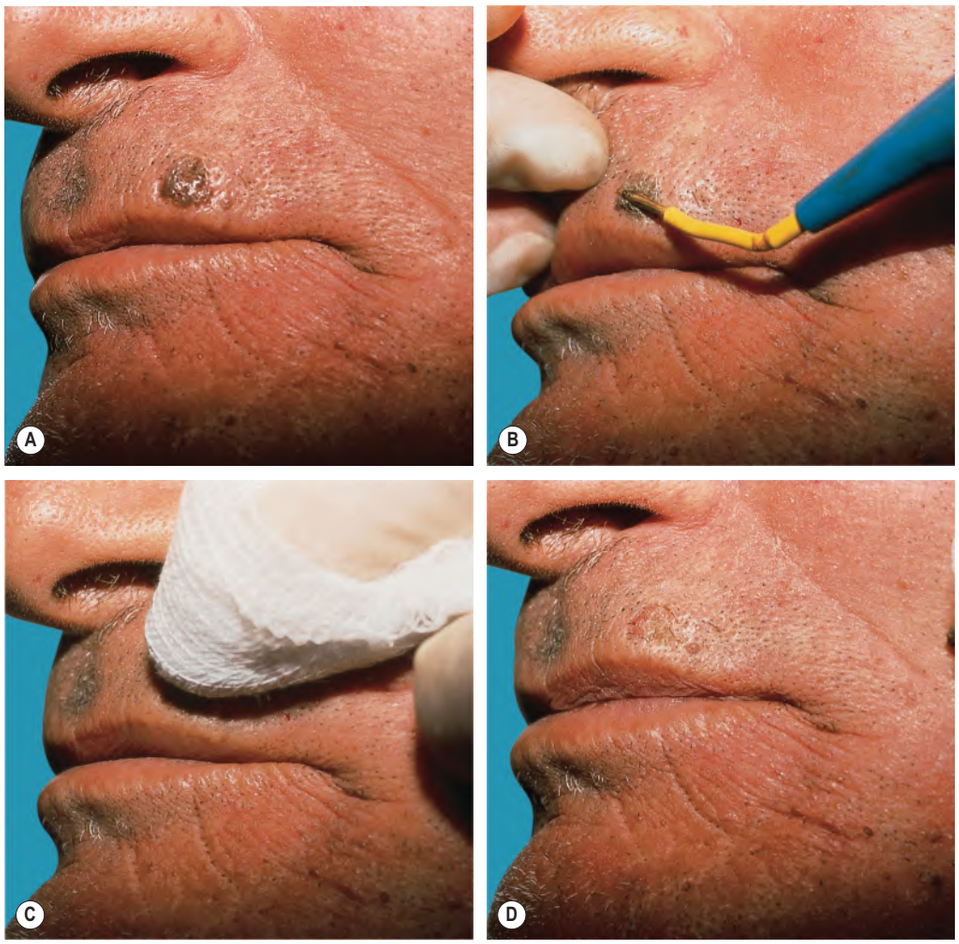

Fig. 140.3 Seborrheic keratosis on the upper lip. A Given its epidermal location, electrosurgical destruction should employ a current that provides the most superficial type of tissue damage. **B** Under local anesthesia, the lesion is treated by electrodesiccation. Delivery of current is stopped when the lesion begins to "bubble". **C** In lieu of a curette, a gauze pad is useful for removing charred tissue after desiccation of superficial lesions. **D** There is minimal bleeding, indicating that damage did not penetrate deeply into the dermis.

Fig. 140.4 Basal cell carcinoma on the right deltoid area, treated by curettage and electrosurgery. A Nodular basal cell carcinoma preoperatively after injection of local anesthesia. **B** The tumor is curetted to debulk all friable tissue. **C** Further curettage, often with a smaller-diameter curette, should proceed in all directions to remove small extensions of tumor. **D** Following thorough curettage, the surface and periphery of the wound are treated by electrocoagulation current to stop bleeding and potentially remove further tumor. **E** Final wound – curettage and electrosurgery have been repeated twice more, until all friable tissue has been removed. Healing occurs over 4–6 weeks, depending upon the site.

Downloaded for Anonymous User (n/a) at Egyptian Knowledge Bank from ClinicalKey.com by Elsevier on March 10, 2024. For personal use only. No other uses without permission. Copyright ©2024. Elsevier Inc. All rights reserved.

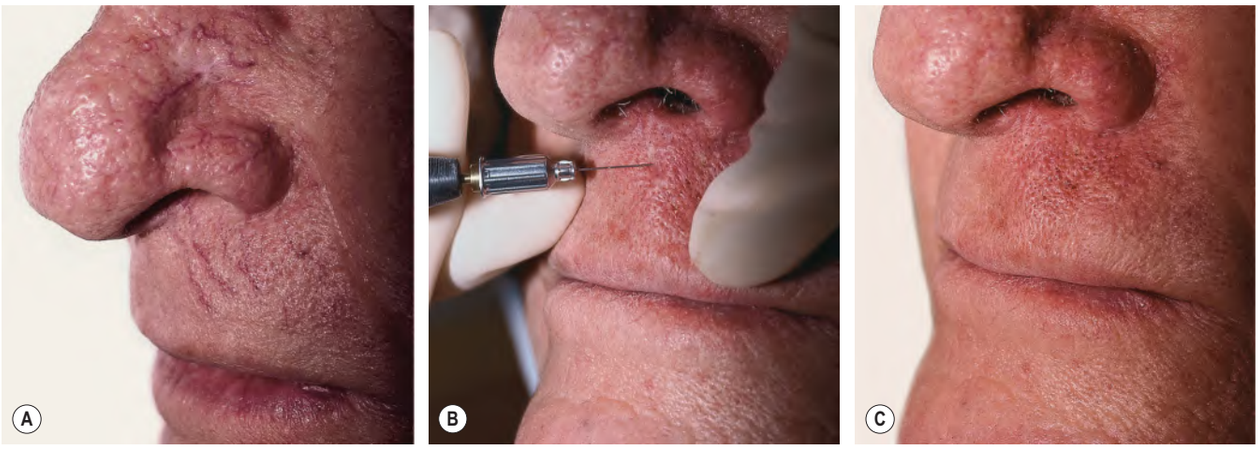

Fig. 140.5 Telangiectasias on nose and upper lip being treated by fine-needle electrocoagulation. A Preoperative photograph shows linear telangiectasias on the nose and upper lip. **B** The electrode consists of a hub adapter with a 30-gauge metal-hubbed needle attached. The machine is energized at a low power setting and the electrode momentarily touches the skin surface, along the length of the vessel being treated, at 3 to 4 mm intervals. The patient experiences some discomfort during the procedure, but this is usually tolerable. **C** The same patient immediately after treatment. This technique is usually performed quickly without anesthesia.

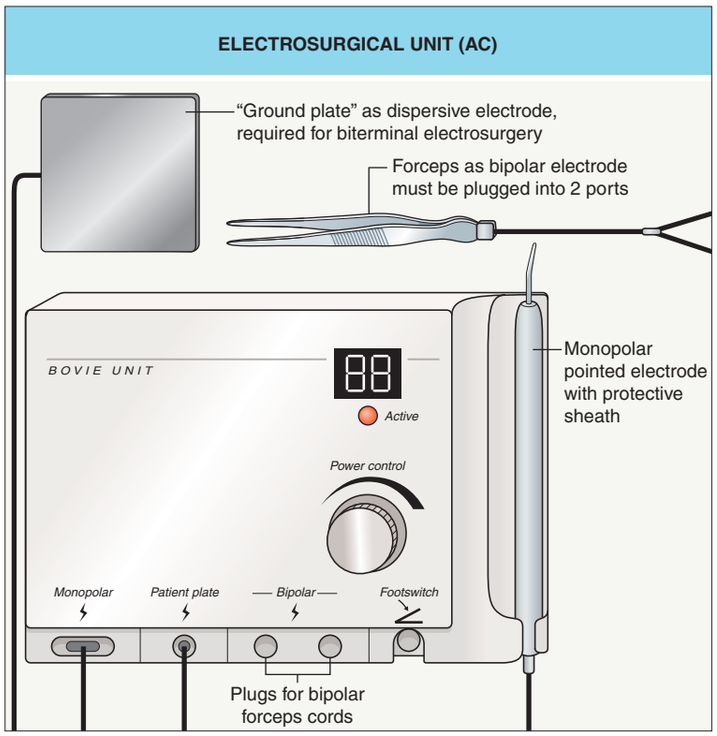

Fig. 140.6 Electrosurgical unit (AC) with attached electrosurgery pencil. The monopolar pencil is used for electrodesiccation and electrofulguration. When used with the grounding plate, it is utilized in a biterminal mode for electrocoagulation. Alternatively, the unit can be used with the bipolar forceps to provide pinpoint electrocoagulation for hemostasis. Bipolar electrocoagulation is also recommended for use in patients with cardiac implantable electronic devices. AC, alternating current.

Electrosection (Cutting)

Electrosection involves the biterminal application of a slightly damped current. The current, of low voltage and high amperage, causes minimal lateral heat spread and tissue damage, and it has the additional advantage of simultaneously achieving hemostasis and cutting. "Pure" cutting can be obtained using a true undamped tube current, which provides the least amount of lateral heat spread and causes vaporization of tissue without hemostasis. Such current has been suggested by Chiarello[18] to be useful in debulking large skin cancers, contouring surrounding skin following shave excisions, scar revision following skin flaps and grafts, and rhinophyma repair. When electrosection is performed using a filtered, fully rectified current, subsequent spot electrocoagulation can be achieved by changing to the electrocoagulation current.

Electrosection can be used to perform rapid and effortless excisions or incisions. Virtually no manual pressure by the operator is required. Electrodes configured as loops, triangles, or diamonds can be used for quick removal of skin tags, papillomas, intradermal nevi, and other exophytic skin lesions. A straight, narrow electrode is most often used to incise the skin and is applied to the tissue in brisk, continuous paintbrush-like strokes. The difference between electrosection and scalpel excision is immediately apparent to the first-time user of electrosection. At the appropriate power setting, the electrode passes smoothly through the tissue like a "hot knife through butter". If perceptible sparking occurs during incision, the power setting is too high; if the electrode "drags", the power setting is too low.

Slightly damped currents cause some charring at the margins of the excised tissue. Therefore, when a specimen suitable for histopathologic analysis is required, the filtered current (see Fig. 140.2) should be used because it does not create significant electrosurgical artifact. It is recommended that the new initiate to electrosection develops technical skills and concepts by practicing on beefsteak before utilizing this technique in the clinical arena.

The major advantage of electrosection over scalpel surgery is that when a blended cutting and coagulating current is utilized, hemostasis is achieved immediately as the incision is made. However, larger blood vessels (>2 mm) require additional spot electrocoagulation at the completion of the excision. Another drawback is that vaporization of the tissue generates a smoke plume, which can be unpleasant for both the patient and the operator and may contain potentially infectious viral particles (see below). Consequently, effective smoke evacuation equipment should be available during such procedures.

Electrosection is extremely useful for achieving relatively bloodless excision of large, bulky lesions, such as acne keloidalis nuchae and rhinophyma (Fig. 140.7), in which the surgical defect is allowed to heal by second intention. Electrosurgical excision followed by primary closure can also be undertaken with no impairment of wound healing, as compared with conventional scalpel surgery. This modality has been used, without complication, to create skin flaps and perform cosmetic facial surgery, including blepharoplasty and rhytidectomy, with excellent outcomes.

VARIATIONS/UNUSUAL SITUATIONS

Cardiac Implantable Electronic Devices

The use of electrosurgery in patients with cardiac implantable electronic devices raises the question of whether the flow of electrical energy during electrosurgery might interfere with the function of these devices[19]. Although modern permanent pacemakers and ICDs have improved shielding technology to guard them from the influence of

Downloaded for Anonymous User (n/a) at Egyptian Knowledge Bank from ClinicalKey.com by Elsevier on March 10, 2024. For personal use only. No other uses without permission. Copyright ©2024. Elsevier Inc. All rights reserved.

Fig. 140.7 Rhinophyma. A Moderately severe rhinophyma in a middle-aged man. **B** Immediately after electrosurgical planing of excess sebaceous glands. Care is taken to perform subtotal removal as very aggressive therapy can result in significant scarring and possible deformity caused by scar contracture. **C** Four weeks later, healing with good cosmetic outcome is noted. During healing, the wound is kept moist with an ointment (e.g. petrolatum) and semi-occlusive dressings.

external electromagnetic currents, prudence requires that a modicum of precaution be taken. If used indiscriminately in these patients, electrosurgery can occasionally trigger skipped beats, reprogramming of a pacemaker, firing of an ICD, asystole, or bradycardia.

Routine precautions recommended when using electrosurgery in patients with cardiac implantable electronic devices include: (1) utilize short bursts of energy that are less than 5 seconds in duration; (2) keep power settings as low as possible; (3) avoid the use of cutting current; and (4) avoid use on the skin around the device. Although recommended in the literature, most dermatologists do not follow specific precautions such as intraoperative monitoring, preoperative cardiology consultation, or postoperative evaluation of the cardiac device by a cardiologist. This may be due to the fact that to date there have been no reported cases of interference with a pacemaker or ICD in a dermatologic setting. Also, at least one article suggests that practical experience of complications due to electrosurgical interference is rare among dermatologic surgeons[20].

There is less risk of potential side effects when the electrosurgical current is confined to a very small area, as is the case when bipolar forceps are used as electrodes. A way to virtually eliminate such risk in very unstable cardiac patients or those with ICDs is to use true electrocautery, rather than other forms of electrosurgery[21]. Although use of this modality may cause more of a burn injury than is seen with true electrosurgery, there is no flow of current to cause electrical interference. In a survey of Mohs surgeons, 34% used electrocautery and 19% used bipolar forceps in patients with pacemakers or ICDs. Among this group, there was only one reported case of interference in one of the electrocautery patients. However, since there is no current flow in true electrocautery, this was likely an error in reporting.

It is the author's belief that the use of either electrocautery or bipolar forceps as electrodes in patients with cardiac implantable electronic devices will eliminate the need for intraoperative monitoring, preoperative cardiology consultation, or postoperative evaluation by a cardiologist in the majority of patients.

POSTOPERATIVE CARE

Standard postoperative wound management, incorporating an ointment (e.g. petrolatum) and/or semi-occlusive dressings, is followed. For superficial skin ablations, such as those following electrodesiccation or electrofulguration, twice-daily application of an ointment such as petrolatum is generally all that is required. An adhesive plaster may be used if the area is prone to rubbing. An eschar forms within a few days and separates in about 10 days. For deeper wounds, in which healing can take 2–4 weeks (or longer on the lower extremities), once- or twice-daily application of an ointment (e.g. petrolatum) followed by an adhesive plaster is recommended. For larger wounds, such as those following rhinophyma repair, Telfa™ sheets are cut to size to cover the defect and kept in place with semi-occlusive paper tape (e.g. Micropore™, 3M Corporation).

COMPLICATIONS

Patients should be warned of the possibility of delayed bleeding and should be reassured that it can, in the vast majority of cases, be controlled by 20–30 minutes of *constant* direct pressure over the wound. Trips to the local emergency room to stop postoperative bleeding are unusual but can occur. Patients should also be advised that for ablative procedures including electrocoagulation, scarring, in the form of a hypopigmented area, may occur.

Other potential hazards of electrosurgery are briefly discussed below.

Fire

There is a risk of fire or explosion if electrosurgical procedures are conducted in the presence of alcohol, oxygen, or bowel gases (methane). Care should be taken to be certain that the operative site is free of alcohol residue, i.e. confirm any alcohol-containing skin preparation has completely dried before proceeding with electrosurgery. Of note, aluminum chloride solutions used for hemostasis can contain over 90% alcohol (v/v). Oxygen is usually not a problem except in the operating room setting. Bowel gases are highly flammable! Use care in the perianal region.

Thermoelectric Burns

Although modern generators are isolated from earth, and are often equipped with sophisticated monitoring systems, current can still be diverted away from the return electrode and cause an accidental burn at the point at which it leaves the patient's body. Alternative pathways occur when the current is diverted from the return electrode and finds an alternative path to return to the generator. When the point of contact between the patient and the grounded object is small, even a relatively low-power current can generate sufficient current density to cause a burn. Grounded objects may include metal parts of the operating table, table accessories, or ECG electrodes. This problem is reduced, but not eliminated, by the use of isolated electrosurgical units, which have little or no connection to the ground.

Microorganism Transmission

The potential exists for transmission of microorganisms either via the electrode[22,23] or via smoke plume inhalation. Neither possibility has been investigated in sufficient depth to yield conclusive results. Practitioners should minimize the risk of possible electrode transmission by using

Downloaded for Anonymous User (n/a) at Egyptian Knowledge Bank from ClinicalKey.com by Elsevier on March 10, 2024. For personal use only. No other uses without permission. Copyright ©2024. Elsevier Inc. All rights reserved.

disposable or sterilized electrodes. Adapters are available that allow disposable metal hypodermic needles to be used as electrodes.

Surgical Smoke

During surgical procedures using a laser or electrosurgical unit, the thermal destruction of tissue creates a smoke by-product. Research studies have confirmed that this smoke plume can contain toxic gases and vapors such as benzene, hydrogen cyanide and formaldehyde, bioaerosols, dead and live cellular material (including blood fragments)[24], and viruses[25]. At high concentrations, the smoke causes ocular and upper respiratory tract irritation in healthcare personnel and creates visual problems for the surgeon. The smoke has unpleasant odors and has been shown to have mutagenic potential[26].

Research by the National Institute for Occupational Safety and Health (NIOSH) has shown that airborne contaminants generated by these surgical devices can be effectively controlled by appropriate ventilation using a portable smoke evacuation system. Smoke evacuators contain a suction unit (vacuum pump), filter, hose, and an inlet nozzle. The smoke evacuator should have high efficiency in airborne particle reduction and should be used in accordance with the manufacturer's recommendations to achieve maximum efficiency. A capture velocity of approximately 100–150 feet per minute at the inlet nozzle is generally recommended. It is also important to choose a filter that is effective in collecting the contaminants. A high-efficiency particulate air (HEPA) filter or equivalent is recommended for trapping particulates. Various filtering and cleaning processes also exist which remove or inactivate airborne gases and vapors. The different filters and absorbers used in smoke evacuators require monitoring and replacement on a regular basis and are considered a possible biohazard requiring proper disposal.

The smoke evacuator hose inlet nozzle must be kept within 2 inches of the surgical site to effectively capture airborne contaminants generated by these surgical devices. The smoke evacuator should be activated at all times when airborne particles are produced during an electrosurgical procedure that generates a significant smoke plume. After each procedure, all tubing distal to the filter must be considered infectious waste and be disposed of appropriately. The filters themselves may be used for the cumulative time specified by the manufacturer before replacement.

ELECTROEPILATION

Electroepilation is the use of electricity for the permanent removal of hair[27]. It predated the development of laser hair removal and is still used, in a variety of forms, by aestheticians and electrologists. The word *electrolysis*, which is used by most people as a generic term to mean the electrical destruction of hair, is technically the use of direct (galvanic) current for hair removal. Hair destruction with an alternating current occurs as a result of the accumulation of heat in the vicinity of the hair bulb and is designated *thermolysis*.

Electrolysis vs Thermolysis

Electrolysis uses direct current to create a destructive chemical reaction at the hair root. The negative electrode (anode) is inserted into the hair follicle (see Fig. 140.1). The positive electrode (cathode) is a moistened pad held in the patient's hand. When direct current is applied, a chemical reaction at the tip of the anode causes the production of sodium hydroxide. The latter acts as a caustic and destroys the hair root. This process may take from 30 to 60 seconds to occur, so pure "galvanic electrolysis" is a tedious procedure to perform. Of note, electrolysis can also be used to treat small telangiectasias (see Fig. 140.1).

Thermolysis relies on heat to cause hair destruction. A high-frequency (13.56 MHz) alternating current is used. As the current passes through tissue, it encounters resistance, causing the current to stall and convert to heat. Current can be applied by the "slow" (manual) technique or the "flash" technique. Lower heat is used over 3–10 seconds in the slow technique. Gentle traction of the hair allows the operator to determine when destruction is complete. The flash technique uses higher heat, delivered by a preset mechanical timer (<1 second). Several such pulses may be required to cause hair root destruction. Theoretically, the flash technique is less painful.

The technique for needle insertion is the same as for electrolysis. A patient hand-held electrode is not required since the patient is not included in the electrical circuit. The speed of thermolysis allows for treatment of much larger areas over a shorter time period. For this reason, it has replaced galvanic electrolysis as the preferred manner of electroepilation. The *blend* is a form of electroepilation that takes advantage of attributes of both electrolysis and thermolysis, by blending the two types of current in one machine. The blend is slower than thermolysis, but may offer some advantages in rate of hair root destruction, particularly for coarser hairs.

Side Effects

Thermolysis and the blend are more painful than classic galvanic electrolysis and the risk of scarring and hair regrowth may be higher. However, highly motivated patients generally tolerate the pain and are treated with 30- to 60-minute sessions once or twice weekly. The use of topical anesthetics under occlusion for 1–2 hours pretreatment decreases the pain in some patients. Scarring is a real risk and is operator-dependent. Generally, when this occurs, it presents as punctate or ice pick-like depressed scars. In some patients, small hypertrophic papules may appear.

Hair regrowth has been reported in the range of 15% to 50%, and this is also technique-dependent. Regrowth may be related, in part, to the hair cycle. Hairs treated while in telogen phase may not experience root destruction. Some electrologists recommend shaving 2 days prior to treatment so that only actively growing hairs will be apparent.

Varying degrees of erythema and edema may be present shortly after the procedure. Postinflammatory hypo- and hyperpigmentation have been reported. The theoretical risk of infections, both local and systemic, exists, but proper skin cleansing helps prevent this problem. Some patients have a higher propensity for developing post-treatment folliculitis and it is recommended that they cleanse with an antibacterial cleanser (e.g. chlorhexidine), before and after treatment. Disposable needles are the norm in the practice of permanent hair removal.

IONTOPHORESIS

In some patients, tap or deionized water iontophoresis can be used successfully to treat localized hyperhidrosis of the palms, soles, or axillae. In this technique, direct electrical current is passed through the treatment site while the patient is in contact with an aqueous ionic solution. The electric current introduces ions from the solution into the patient's skin and appears to inhibit sweating by occluding the eccrine ducts at the level of the stratum corneum[28].

A battery-powered unit for home use (Drionic®) is available. It is more effective for treatment of palmoplantar hyperhidrosis than for axillary hyperhidrosis. Cessation of sweating usually requires treatment of each palm or sole with 20 mA of current for 30 minutes daily. The recent use of botulinum toxin type A injections for hyperhidrosis has provided many hyperhidrosis sufferers with a more efficient and longer-lasting treatment modality, albeit at greater expense.

FUTURE TRENDS

Interest and innovation in electrosurgery have actually increased over the past three decades, since continuous wave CO_2 laser systems were introduced. Practitioners came to realize that superficial ablation, deep ablation, and tissue incision with immediate hemostasis were available through electrosurgery without the need for expensive laser systems. As examples, specially adapted electrosurgery equipment that utilizes electricity to remove the epidermis and upper dermis for facial skin resurfacing has been introduced[29] as has the use of electrosurgical cutting current (Ellman® Surgitron®) to resurface surgical scars. The latest electrosurgical development is use of a standard radiosurgery device (Surgitron® Dual RF™) for non-ablative tightening of skin laxity[30]. Radiofrequency current produces heat because of resistance in the dermis and subcutaneous tissue. When heated, collagen fibrils will denature and contract, presumably leading to the observed tissue tightening.

Downloaded for Anonymous User (n/a) at Egyptian Knowledge Bank from ClinicalKey.com by Elsevier on March 10, 2024. For personal use only. No other uses without permission. Copyright ©2024. Elsevier Inc. All rights reserved.

REFERENCES

1. Blankenship ML. Physical modalities. Electrosurgery, electrocautery and electrolysis. *Int J Dermatol*. 1979;18:443–452.
2. Weyer C, Siegle RJ, Girard G, Eng P. Investigation of hyfrecators and their *in vitro* interference with implantable cardiac devices. *Dermatol Surg*. 2012;38:1843–1848.
3. Mitchell JP, Lumb GN. Principles of surgical diathermy and its limitations. *Br J Surg*. 1962;50:314–320.
4. d'Arsonval A. Action physiologique des courants alternatifs. *Soc Biol*. 1891;43:283–286.
5. d'Arsonval A. Action physiologique des courants alternatifs à grande fréquence. *Arch Physiol Norm Path*. 1893;5:401–408.
6. Rivière AJ. Action des courants de haute fréquence et des effleuves du résonateur Oudin sur certaines tumeurs malignes. *J Med Intern*. 1900;4:776–777.
7. Pozzi M. Remarques sur la fulguration. *Bull Assoc Franc Cancer*. 1909;2:64–69.
8. Doyen D. Sur la destruction des tumeurs cancéreuses accessibles par la méthode de la voltaisation bipolaire et de l'électro-coagulation thermique. *Arch Elec Med Exp Clin*. 1909;17:791–795.
9. Clark WL. Oscillatory desiccation in the treatment of accessible malignant growths and minor surgical conditions: a new electrical effect. *J Adv Therap*. 1911;29:169–183.
10. Wyeth GA. Endothermy, surgical adjunct in accessible malignancy and precancerous conditions. *Surg Gynec Obstet*. 1923;36:711–714.
11. Wyeth GA. The endotherm. *Am J Electrotherapeut Radiol*. 1924;42:186–187.
12. Cushing H. Electro-surgery as an aid to the removal of intracranial tumors, with a preliminary note on a new surgical-current generator by WT Bovie, PhD. *Surg Gynec Obstet*. 1928;47:751–752.
13. Goldwyn RM. Bovie: the man and the machine. *Ann Plast Surg*. 1979;2:135–153.
14. Taheri A, Mansoori P, Sandoval LF, et al. Electrosurgery: part I. Basics and principles. *J Am Acad Dermatol*. 2014;70:591.e1–14.
15. Taheri A, Mansoori P, Sandoval LF, et al. Electrosurgery: part II. Technology, applications, and safety of electrosurgical devices. *J Am Acad Dermatol*. 2014;70:607.e1–12.
16. Pollack SV. *Electrosurgery of the Skin*. New York: Churchill Livingstone; 1991.
17. Sebben JE. *Cutaneous Electrosurgery*. Chicago: Year Book Medical Publishers; 1989.
18. Chiarello S. Controlled vaporization of tumor tissue utilizing radio frequency cutting current through a blunt hockey stick scalpel or radio frequency knife. *Dermatol Surg*. 1998;24:158–160.
19. Riordan AT, Gamache C, Fosko SW. Electrosurgery and cardiac devices. *J Am Acad Dermatol*. 1997;37:250–255.
20. El-Gamal HM, Dufresne Jr RG, Saddler K. Electrosurgery, pacemakers and ICDs: a survey of precautions and complications experienced by cutaneous surgeons. *Dermatol Surg*. 2001;27:385–390.
21. Wilson JH, Lattner S, Jacob R, Stewart R. Electrocautery does not interfere with the function of the automatic implantable cardioverter defibrillator. *Ann Thorac Surg*. 1991;51:225–226.
22. Sherertz EF, Davis GL, Rice RW, et al. Transfer of hepatitis B virus by contaminated reusable needle electrodes after electrodesiccation in simulated use. *J Am Acad Dermatol*. 1986;15:1242–1246.
23. Bennett RG, Kraffert CA. Bacterial transference during electrodesiccation and electrocoagulation. *Arch Dermatol*. 1990;126:751–755.
24. Berberian BJ, Burnett JW. The potential role of common dermatologic practice techniques in transmitting disease. *J Am Acad Dermatol*. 1986;15:1057–1058.
25. Sawchuck WS, Weber PJ, Lowy DR, et al. Infectious papillomavirus in the vapor of warts treated with carbon dioxide laser or electrocoagulation: detection and protection. *J Am Acad Dermatol*. 1989;21:41–49.
26. Tomita Y, Mihashi S, Nagata K, et al. Mutagenicity of smoke condensates induced by CO_2-laser irradiation and electrocauterization. *Mutat Res*. 1981;89:145–149.
27. Pollack SV, Grekin RC. Electrosurgery and electro-epilation. In: Roenigk RK, Roenigk HH, eds. *Dermatologic Surgery: Principles and Practice*. 2nd ed. New York: Marcel Dekker; 1996:219–231.
28. Sato K, Timm DE, Sato F, et al. Generation and transit pathway of H^+ is critical for inhibition of palmar sweating by iontophoresis in water. *J Appl Physiol*. 1993;75:2258–2264.
29. Grekin RC, Tope WD, Yarborough Jr JM, et al. Electrosurgical facial resurfacing: a prospective multi-center study of efficacy and safety. *Arch Dermatol*. 2000;136:1309–1316.
30. Rusciani A, Curinga G, Menichini G, et al. Nonsurgical tightening of skin laxity: a new radiofrequency approach. *J Drugs Dermatol*. 2007;6:381–386.

Downloaded for Anonymous User (n/a) at Egyptian Knowledge Bank from ClinicalKey.com by Elsevier on March 10, 2024. For personal use only. No other uses without permission. Copyright ©2024. Elsevier Inc. All rights reserved.